

# Disastrous Complications Following a Bilateral, Same-Day Laser In Situ Keratomileusis (LASIK) Procedure

**I**N 1998, a 37-year-old woman underwent bilateral same-day laser in situ keratomileusis (LASIK) surgery. The preoperative refraction was  $-6$  diopters (D) for each eye. The surgery on the right eye was uncomplicated. On the left eye, the procedure was complicated by corneal perforation, probably due to misassembly of an older-generation microkeratome with a removable spacer plate. Despite surgical repair, the outcome was very bad and on the day of our examination, 1 year after surgery, she had no light perception and the slitlamp findings showed phthisis bulbi (**Figure 1**).

In her right eye eye, there was an undercorrection of 2 D. Despite the complication in the left eye eye, the surgeon decided to perform ad-

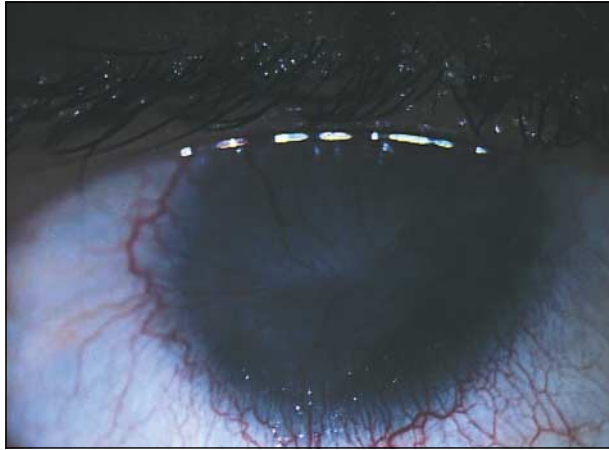ditional surgery. Instead of lifting the first flap or recutting a flap, he performed a photorefractive keratectomy on top of the first flap. The eye developed an excessive healing reaction with the formation of visually significant haze that decreased her visual acuity to less than 20/200 OD (**Figures 2, 3, and 4**).

After consultation with those in our center where procedural outcome problems are handled, we advised her to wait and see if the haze decreased thus permitting the recovery of some vision without any further intervention, even though she is seriously handicapped by her current state of vision. Our alternative to this approach would have been to perform a lamellar keratoplasty to attempt to improve on her vision.

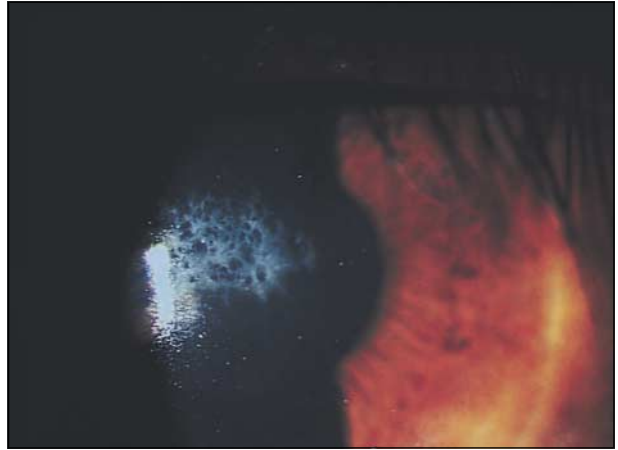Corneal perforation using a microkeratome is particularly unusual and has become rare with newer microkeratomes. Thus, this case report does not question the legitimacy of a sequential bilateral LASIK procedure, but it does underscore that disastrous complications can occur. When they do, conservative treatment must be preferred to avoid additional difficulties.

Sylvie M. Velou, MD  
Joseph Colin, MD  
Bordeaux, France

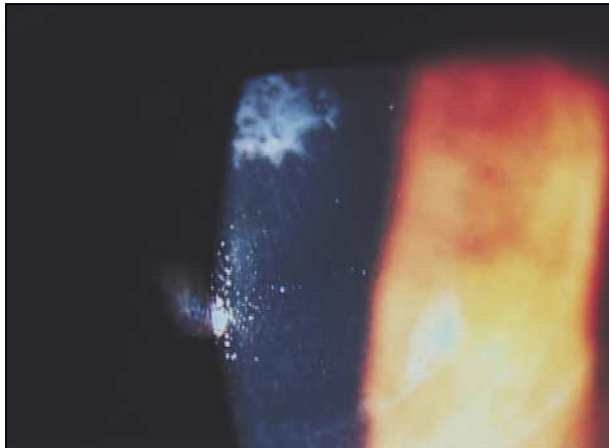
Reprints: Sylvie M. Velou, MD, Place Amélie Raba Léon, 33076 Bordeaux CEDEX, France (e-mail: svelou@chu-bordeaux.fr).



**Figure 1.** Phthisis bulbi in the left eye after corneal perforation due to microkeratome misassembly.



**Figure 2.** Haze after photorefractive keratectomy retreatment of the undercorrection of the right eye.



**Figure 3.** Haze and limit of the corneal flap in the right eye.



**Figure 4.** Limit of the corneal flap in the right eye.