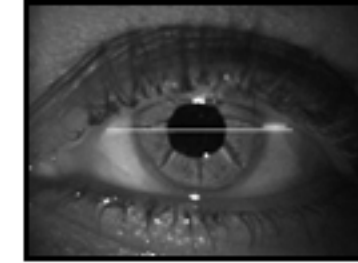


Image Analysis Report



Patient name: [REDACTED]
Date of birth: [REDACTED]
Patient ID: [REDACTED]

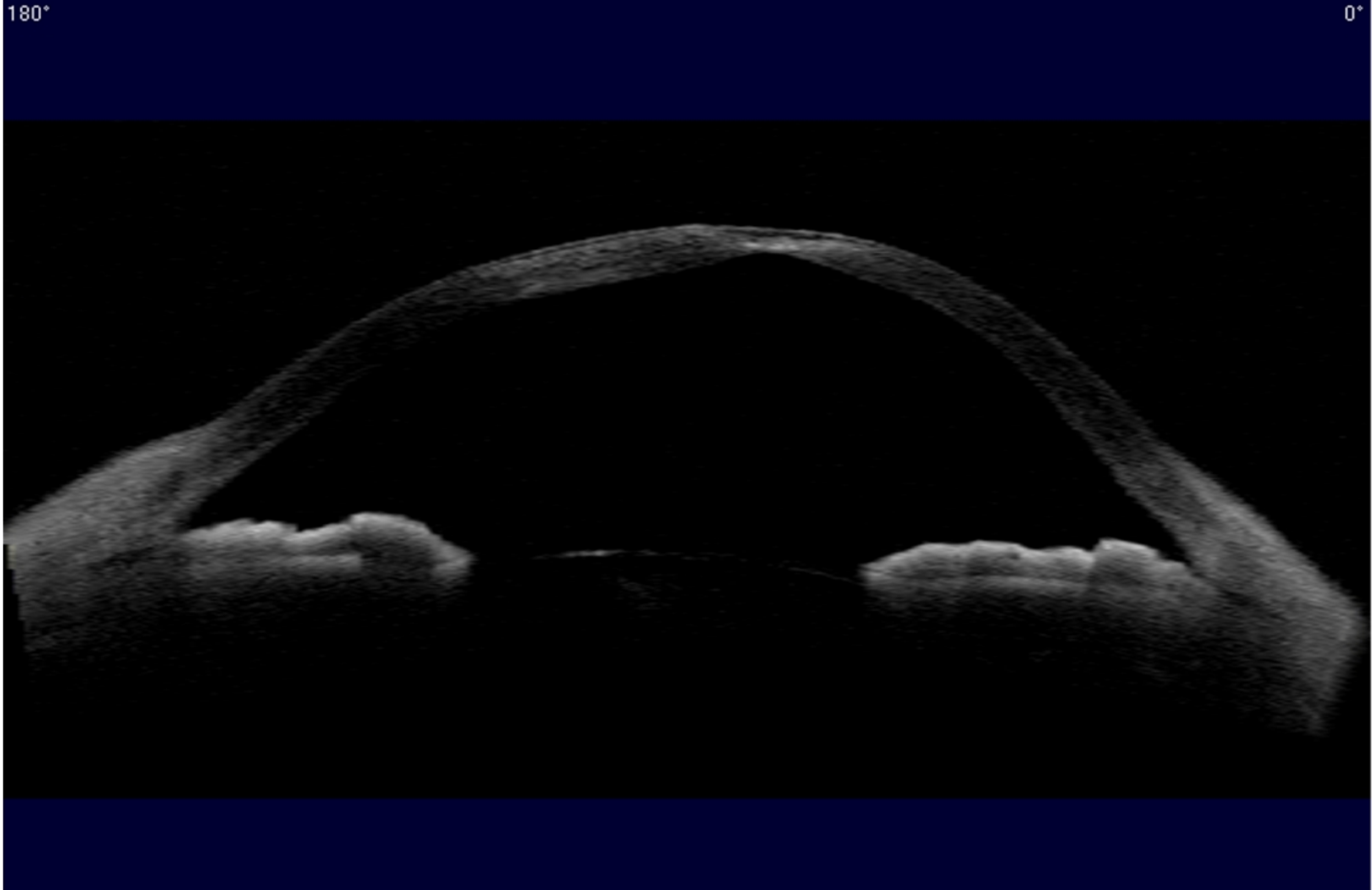
Rx: Sphere: 0.0
Cylinder: 0.0
Axis: 0.0
Fixation Angle: 0.0
Polarization: 41.0
Orientation: 0.0



Visante™ OCT
ANTERIOR SEGMENT IMAGING

Exam date: 1/19/2010 11:59:18 AM

Protocol: Edward Boshnick, O.D.
Scan: Enhanced Anterior Segment Single



Planning

Institution: [REDACTED] Date: 1/19/2010 12:10:30 PM Serial Number: -
Planner: [REDACTED] Station: [REDACTED] Software Ver: [REDACTED]

Acquisition

Institution: CZM Serial Number: 1000-1815
Operator: VisanteTech Station: [REDACTED] Software Ver: 3.0.0.139