

# Image Analysis Report



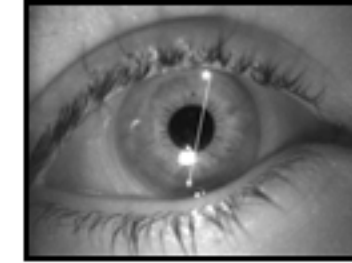
Patient name:



Date of birth:

Patient ID:

Rx: Sphere: 0.0  
Cylinder: 0.0  
Axis: 0.0  
Fixation Angle: 0.0  
Polarization: 41.0  
Orientation: 79.0

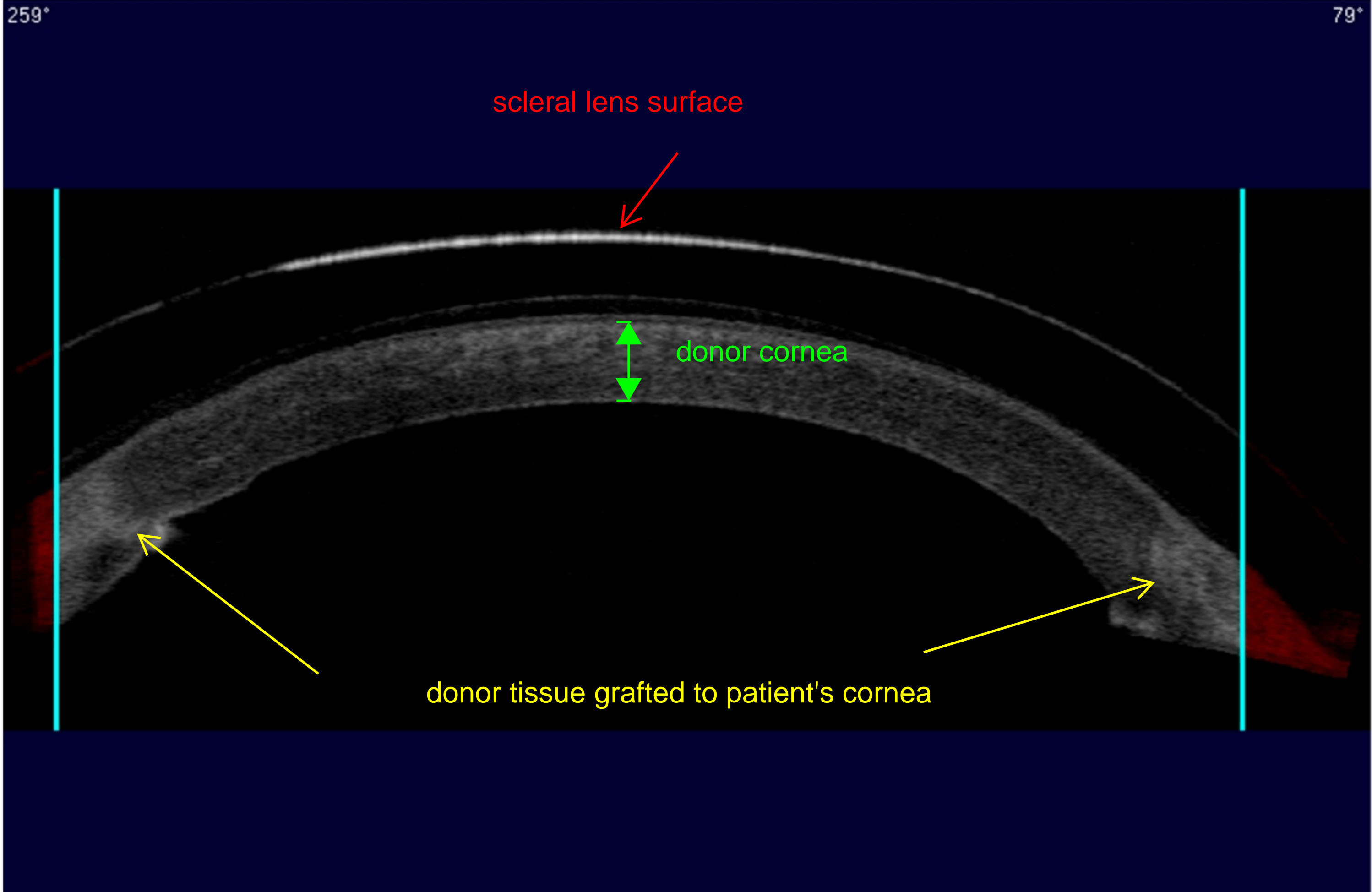


**OD**

**Visante™ OCT**  
ANTERIOR SEGMENT IMAGING

Exam date: 1/14/2010 10:03:20 AM

Protocol: Edward Boshnick, O.D.  
Scan: Enhanced High Res. Corneal



## Planning

Institution:  
Planner:

Date: 1/14/2010 10:05:14 AM  
Station:

Serial Number: -  
Software Ver:

## Acquisition

Institution: CZM  
Operator: VisanteTech

Station:

Serial Number: 1000-1815  
Software Ver: 3.0.0.139